



CASE REPORT

Percutaneous transcatheter closure of aorto-right ventricular fistula using the Amplatzer duct occluder



Emmanouil Petrou*, Ioannis Iakovou, Evangelos Leontiadis, Panagiota Kourkouveli, Spyridon Rammos, George Karatasakis

Division of Cardiology, Onassis Cardiac Surgery Center, Athens, Greece

Received 17 October 2014; accepted 25 December 2015
Available online 25 June 2016

KEYWORDS

percutaneous closure;
aorto-right ventricular fistula

Abstract The occurrence of aorto-right ventricular fistula after an aortic valve replacement is rare. If it remains untreated, this condition can result in heart failure and could thus significantly compromise patient survival. Surgical closure is the treatment of choice; however, transcatheter closure has been attempted with relatively acceptable results. Here, we report on a patient who presented with heart failure with an aorto-right ventricular fistula that was present for nine years following aortic valve replacement. Successful transcatheter closure of the fistula with the use of the Amplatzer duct occluder was performed, suggesting that the percutaneous approach is an efficient technique for the treatment of such fistulae.

© 2016 Hellenic Cardiological Society. Publishing services by Elsevier B.V. This is an open access article under the CC BY-NC-ND license (<http://creativecommons.org/licenses/by-nc-nd/4.0/>).

1. Introduction

Aorto-cardiac fistulas are relatively rare. They are often a complication of surgery, trauma or infective endocarditis. A

2 × 2 cm contact surface between the aorta above the right coronary cusp and the right ventricular outflow tract is the target area for an aorto-right ventricular fistula.¹

2. Case presentation

A 73-year-old woman was admitted to our hospital for a scheduled percutaneous transcatheter closure of an iatrogenic aorto-right ventricular fistula. The patient had a history consistent with dyspnea at rest over the past three weeks. Nine years ago, she underwent aortic valve replacement with a bileaflet mechanical prosthetic valve

* Corresponding author. Emmanouil Petrou, Division of Cardiology, Onassis Cardiac Surgery Center, 356 Syggrou Ave., GR-17674, Athens, Greece. Tel.: +30 2109493000; fax: +30 2102751028.

E-mail address: emmgpetrou@hotmail.com (E. Petrou).

Peer review under responsibility of Hellenic Cardiological Society.

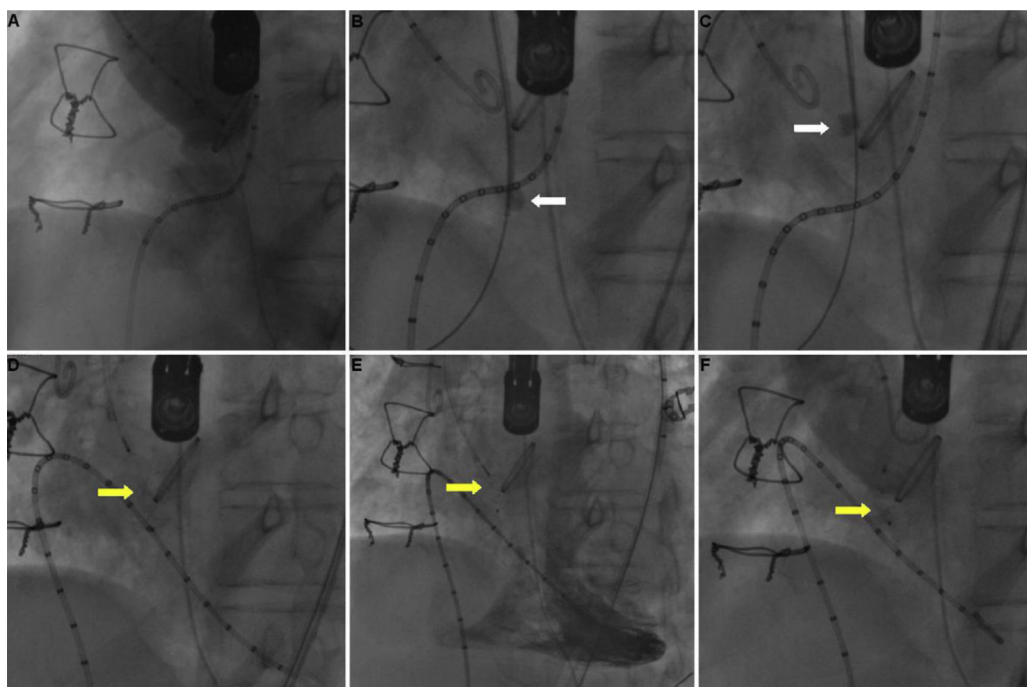


Figure 1 A. Aortography demonstrating the 4 mm-wide aorto-right ventricular fistula, B, C. The guide-wire of the duct occluder (white arrow) was promoted directly through the right ventricle to the fistula and the aortic root, D. Duct occluder (yellow arrow) apposition procedure, E. Right ventriculography for the assessment of the duct occluder position, F. Repeat aortography showing an acceptable occlusion of the aorto-right ventricular fistula with minor residual flow.

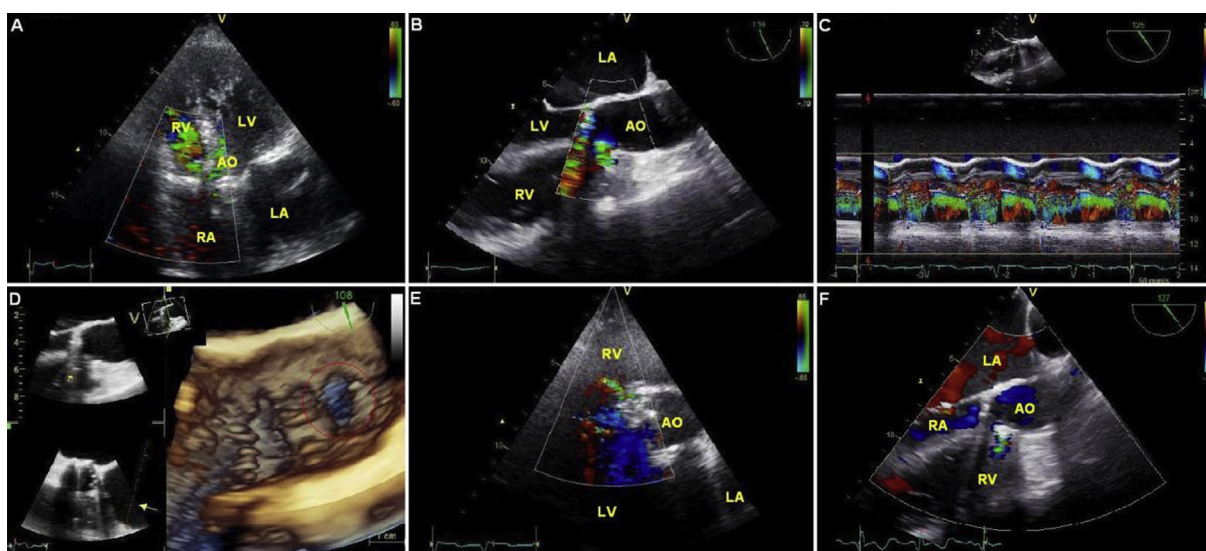


Figure 2 A. Transthoracic echocardiography, B. Transesophageal echocardiography confirming the communication from the aorta to the right ventricle at the level of the right coronary cusp. C. Continuous flow of the communication between the aorta and the right ventricle, D. Three dimensional transesophageal echocardiographic visualization of the aorto-right ventricular fistula, E. Post-procedural transthoracic echocardiography, F. Post-procedural transesophageal echocardiography showing minor residual flow between the aorta and the right ventricular fistula. (AO: Aortic root; LA: Left Atrium; LV: Left Ventricle; RA: Right Atrium; RV: Right Ventricle).

for aortic stenosis of rheumatic etiology (Fig. 1). In the first post-operative echocardiogram, a communication between the aortic root and the right ventricle with continuous flow (Fig. 2C) was diagnosed. The patient was regularly followed

up with for nine years, with no evidence of clinical or echocardiographic deterioration.

Upon admission, the patient was on atrial fibrillation; the physical examination was compatible with right heart

failure. Transthoracic (Fig. 2A) and two-dimensional (2D) (Fig. 2B)/three-dimensional (3D) (Fig. 2D) transesophageal echocardiography confirmed the communication from the aorta to the right ventricle at the level of the right coronary cusp. The right ventricular systolic pressure was over 40 mmHg. Aortography demonstrated the 4 mm-wide aorto-right ventricular fistula (Fig. 1A). Therefore, we performed percutaneous closure of the fistula using fluoroscopy, under regional anesthesia and sedation, with the use of an Amplatzer duct occluder (Fig. 1 – yellow arrow). In our case, and, to our knowledge, the first report, the aorto-right ventricular fistula was accessed in a retrograde manner; that is, the guide-wire of the duct occluder was promoted directly through the right ventricle to the fistula and the aortic root (Fig. 1 – white arrow). Right ventriculography (Fig. 1E) was performed to assess the occluder position.

Repeat aortography (Fig. 1F), transthoracic (Fig. 2E) and transesophageal (Fig. 2F) echocardiography showed an acceptable occlusion of the aorto-right ventricular fistula with minor residual flow. Symptoms rapidly improved and the patient was discharged with explicit instructions and medication.

3. Discussion

Aorto-right ventricular fistulas are very rare. Most of cases are caused by rupture of the sinus of Valsalva or endocarditis but are also less frequently caused by trauma or in association with valve replacement.² In the case of aortic valve replacement, iatrogenic injury of the septum, aggressive debridement of the annulus and inappropriate suturing of the mechanical valve onto the membranous portion of the ventricular septum may be reasons for fistula formation.³ There are also reports of primary suture failure (dehiscence) and infective endocarditis associated paravalvular leakages.⁴ Aortic dissection as a cause of aorto-right ventricular fistula has also been reported in the literature.⁵ Recently, the formation of such a fistula as a complication of transcatheter aortic valve implantation has been reported, indicating erosion by the mechanical prosthetic valve struts as the possible mechanism for fistula formation.⁶

The clinical presentation of an aorto-right ventricular fistula depends on its etiology as well as on the size of the shunt. Upon clinical examination, a continuous murmur, a thrill or the combination of both may be present.⁷ Patients with a small aorto-right ventricular fistula may be completely asymptomatic. However, when the shunt is significant or comorbidities cause decompensation of a medium-size fistula, as in our case, the patient may present with manifestations of heart failure. Although aortography is the gold standard for the diagnosis of an aorto-right ventricular fistula, non-invasive modalities such as contrast-enhanced computed tomography, magnetic resonance imaging and especially transthoracic and/or transesophageal echocardiography are currently preferred.⁸

The decision to close an aorto-right ventricular fistula depends on the size of the shunt and the clinical characteristics of the patient. Indications for fistula closure include right and/or left heart failure, pulmonary hypertension and hemolytic anemia.⁹ Surgical closure remains the treatment of choice; however, transcatheter closure has been attempted with relatively acceptable results. The devices used for a percutaneous transcatheter closure of aorto-right ventricular fistulas include: a coil, an Amplatzer atrial septal occluder, an Amplatzer muscular ventricular septal defect occluder, an Amplatzer vascular plug and, as in our case, an Amplatzer duct occluder.^{9,10}

In conclusion, aorto-right ventricular fistulas are an important complication of aortic valve replacement. Closure of such fistulae with the Amplatzer duct occluder in selected patients has been sporadically reported but could prove to be a useful procedure.

Conflicts of interest

None.

References

- Walpot J, Klazen C, Hokken R, Sorgedraeger J, Hoevenaer M, den Braber J. Aorto-right ventricular fistula as an occasional finding. *Eur J Echocardiogr.* 2005;6:65–66.
- Miller DL, Morris JJ, Schaff HV, Mullany CJ, Nishimura RA, Orszulak TA. Reoperation for aortic valve periprosthetic leakage: identification of patients at risk and results of operation. *J Heart Valve Dis.* 1995;4:160–165.
- Roy D, Saba S, Grinberg I, et al. Aorto-right ventricular fistula: a late complication of aortic valve replacement. *Texas Heart Inst J.* 1999;26:140–142.
- Lorenz J, Reddy CV, Khan R, Hoover E, Hsu HK, El-Sherif N. Aorto-right ventricular shunt following aortic valve replacement. *Chest.* 1983;83:922–925.
- Park H, Park TH, Lee DY, et al. A case of aortic dissection with fistula from aorta to right ventricle. *Korean Circ J.* 2012;42:629–631.
- Pilgrim T, Meier B, Wenaweser P. Aorto-right ventricular fistula after transfemoral aortic valve implantation. *J Invasive Cardiol.* 2010;22:E30–E31.
- Najib MQ, Ng D, Vinales KL, Chaliki HP. Aorto-right ventricular fistula: A complication of aortic valve replacement. *Ann Thorac Cardiovasc Surg.* 2012;18:64–67.
- Samuels LE, Kaufman MS, Rodriguez-Vega J, Morris RJ, Brockman SK. Diagnosis and management of traumatic aorto-right ventricular fistulas. *Ann Thorac Surg.* 1998;65:288–292.
- Karapinar H, Kucukdurmaz Z, Gumrukcuoglu HA, Kayancicek H, Gul I, Yilmaz A. Treatment strategies for aorto-right ventricular fistula associated with aortic and/or mitral valve replacements: a case report with a review of the literature. *Post Kardiol Interw.* 2011;2:182–184.
- Dussailant GR, Romero L, Ramirez A, Sepúlveda L. Successful percutaneous closure of paraprosthetic aorto-right ventricular leak using the Amplatzer duct occluder. *Catheter Cardiovasc Interv.* 2006;67:976–980.