



CASE REPORT

A complex transcatheter mitral valve replacement and repair for the treatment of refractory severe mitral regurgitation



Jose F. Condado ^a, Vasilis C. Babaliaros ^{a,*}, Vinod H. Thourani ^b,
Hanna K. Jensen ^b, Dennis W. Kim ^c, Brian W. Kaebnick ^a,
Peter C. Block ^a, Stamatios Lerakis ^a

^a Structural Heart and Valve Center, Divisions of Cardiology, Emory University School of Medicine, Atlanta, GA, USA

^b Cardiothoracic Surgery, Emory University School of Medicine, Atlanta, GA, USA

^c Division of Pediatric Cardiology, Emory University School of Medicine, Atlanta, GA, USA

Received 9 December 2014; accepted 18 June 2015

Available online 23 January 2017

KEYWORDS

Transcatheter mitral valve replacement;
Valve-in-valve;
Valve-in-ring

Case presentation

A 65-year-old male was referred for transcatheter mitral valve replacement after having recurrent symptomatic and severe Mitral regurgitation (MR). One-year prior, he underwent a surgical mitral valve repair with a 32 mm Carpentier-Edwards Physio Annuloplasty Ring (Edwards Lifesciences Corporation, Irvine, CA, USA) (Figure 1A). His

MR recurred after surgery and two additional surgical attempts to correct his regurgitation were aborted because of severe and diffuse chest fibrosis (re-do sternotomy and right lateral thoracotomy approaches). Baseline 3D transesophageal echocardiogram (TEE) confirmed mitral ring diameters of 21 mm by 29 mm (Figure 1B).

We initially performed a transcatheter mitral valve-in-ring replacement with a 26 mm Edward Sapien valve (Edwards Lifesciences) (Figure 2A). However, intraoperative TEE revealed severe central MR secondary to a prolapsing native anterior leaflet interfering with closure of the Sapien valve (Figure 2b and c). We corrected this residual MR by placing a transcatheter Melody Valve (Medtronic, Minneapolis, MN, USA) mounted on a 24 mm balloon-in-balloon (NuMED, Inc. Hopkinton, NY, USA) further into the atrium away from the prolapsing leaflet (Figure 2D). Hemodynamics markedly improved despite some residual paravalvular leak (PVL) (Figure 2E and F).

In-hospital Cardiac Magnetic Resonance (CMR) measured a regurgitant fraction of 36% consistent with moderate to severe PVL. The patient was taken to the cardiac catheterization laboratory for transcatheter PVL closure, which was successfully performed with a 6 mm and an 8 mm Amplatzer Vascular Plug II (Saint Jude Medical, Saint Paul, MN, USA) (Figure 3). A second CMR showed a regurgitant fraction of 17% consistent with mild MR. The patient was

* Corresponding author. Vasilis Babaliaros, MD, Emory University Hospital, F606 1364 Clifton Road, Atlanta, GA, 30322, USA. Tel.: +1 404 712 7667; fax: +1 404 712 5622.

E-mail address: vbabali@emory.edu (V.C. Babaliaros).

Peer review under responsibility of Hellenic Cardiological Society.

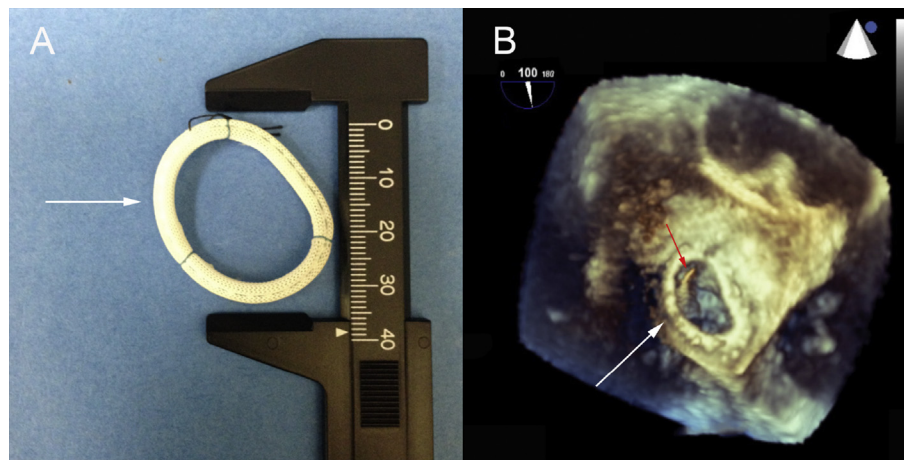


Figure 1 32 mm Carpentier-Edwards Physio Annuloplasty Ring. A) Ring oval morphology at baseline (arrow) and B) Pre-procedural 3D Transesophageal echocardiogram with oval mitral ring (white arrow), diameters of 21 mm by 29 mm and a wire crossing the valve (red arrow).

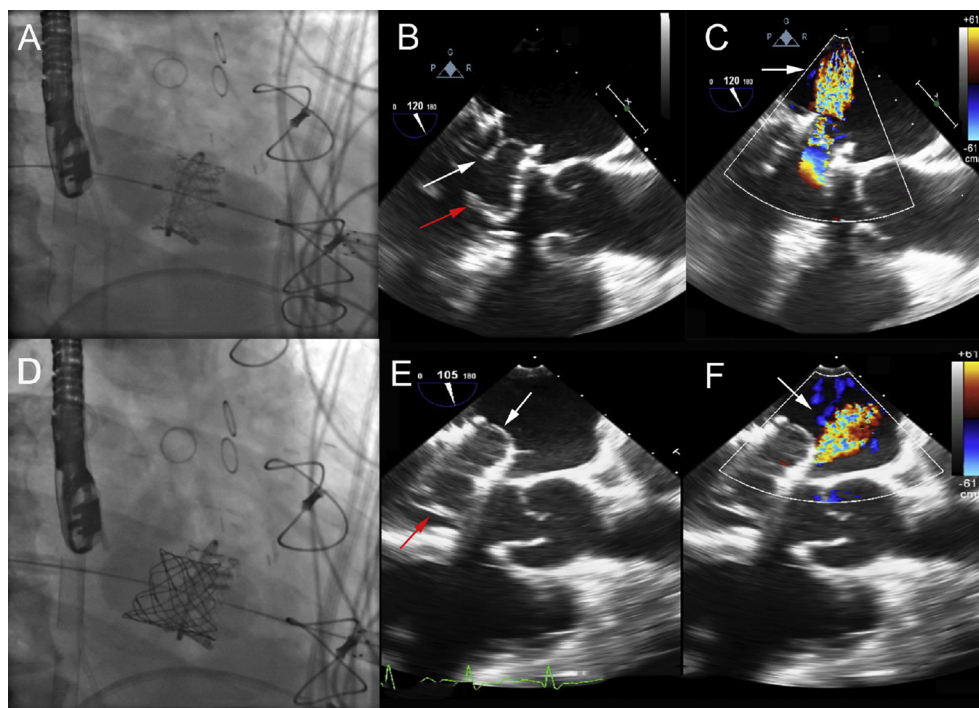


Figure 2 Transcatheter mitral valve-in-ring and valve-in-valve replacement. A) A 26 mm Edwards Sapien valve was deployed at the level of the mitral valve ring using a transapical approach. B) Intraoperative transesophageal echocardiogram (TEE) after mitral valve-in-ring replacement revealed native valve leaflets (white arrow) precluding closure of the prosthetic leaflets (red arrow) with resulting C) severe central MR by color Doppler (arrow). D) A 22 mm Melody valve was deployed further into the atrium away from the prolapsing leaflet. E) TEE after mitral valve-in-valve replacement revealed functioning transcatheter valve leaflets (red arrow) with non-interfering native valve leaflets (white arrow) F) Color Doppler showed resolution of central mitral regurgitation but residual paravalvular leak (arrow).

discharged with marked clinical improvement and has remained stable on medical management.

Discussion

Transcatheter Mitral Valve-in-Ring and Mitral Valve-in-Valve procedures can be an alternative to surgical valve

replacement in patients with high surgical risk. The feasibility of this technique has been proven in animal studies,¹ case series and case reports.²⁻⁴ Our case emphasizes some of the important technical challenges of Mitral valve-in-ring procedures that occur because of the absence of mitral valve specific devices, the complex mitral valve anatomy including prolapsing leaflets, and the different size mitral rings. The

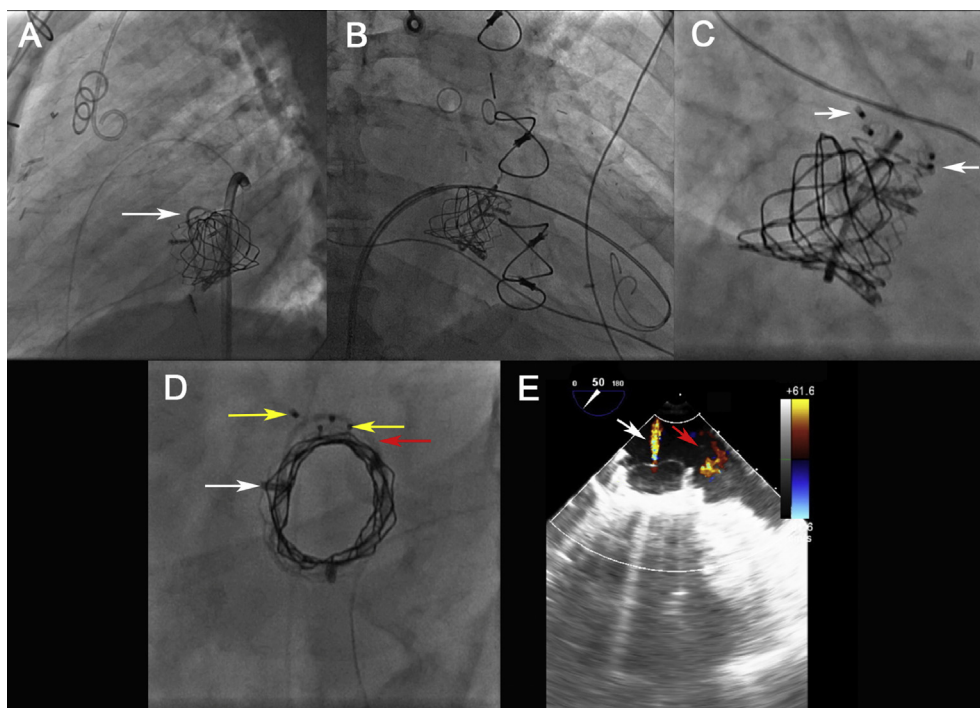


Figure 3 Paravalvular leak (PVL) closure. A) Fluoroscopy revealed PVL space between percutaneous valve and surgical mitral ring (arrow). B) PVL space was cannulated with a wire and C) closed with a 6 mm and an 8 mm Amplatzer Vascular Plugs II (arrows). D) Final fluoroscopy revealed percutaneous valves (white arrow) with the residual PVL space between the valve and the oval mitral ring (red arrow), which was closed by the two vascular plugs (yellow arrows). E) Final transesophageal echocardiogram (TEE) revealed minimal central MR (white arrow) and mild residual paravalvular leak (red arrow).

transcatheter valve type and size must be determined by using multimodality imaging that considers these anatomic characteristics. The oval shape of the ring favors the creation of PVL when implanting the currently available transcatheter valves. Vascular plugs may be used to overcome this problem.

Disclosures

Peter Block MD, FACC is a Direct Flow stock holder, Medtronic consultant and St Jude Medical consultant. Vinod Thourani is a consultant for Edwards Lifesciences, Maquet, St Jude Medical, Sorin, and Directflow Medical. He is also co-founder and stock holder of Apica. Vasilis Babaliaros MD, FACC is a consultant for DirectFlow Medical and St Jude Medical. The other authors have nothing to disclose.

References

1. Shuto T, Kondo N, Dori Y, et al. Percutaneous transvenous Melody valve-in-ring procedure for mitral valve replacement. *J Am Coll Cardiol*. 2011 Dec 6;58(24):2475–2480.
2. De Weger A, Ewe SH, Delgado V, Bax JJ. First-in-man implantation of a trans-catheter aortic valve in a mitral annuloplasty ring: novel treatment modality for failed mitral valve repair. *Eur J Cardiothorac Surg*. 2011 Jun;39(6):1054–1056.
3. Petronio A, Giannini C, De Carlo M, Guarracino F. Antegrade percutaneous valve implantation for mitral ring dysfunction, a challenging case. *Catheter Cardiovasc Interv*. 2012 Oct 1;80(4):700–703.
4. Seiffert M, Conradi L, Baldus S, et al. Transcatheter mitral valve-in-valve implantation in patients with degenerated bioprostheses. *JACC Cardiovasc Interv*. 2012 Mar;5(3):341–349.